

An Atypical Presentation of Giant Meckel's Diverticulitis: A Case Report

Leo Feinberg¹, Charlotte Morris², Ananth Srinivasan¹, Pratik Bhattacharya¹, K Charan², Shafquat Zaman^{1*}

¹Sandwell and West Birmingham Hospitals NHS Trust, Sandwell General Hospital, West Midlands, United Kingdom

²George Eliot NHS Trust, College Street, Nuneaton, Warwickshire, United Kingdom

*Corresponding author:

Shafquat Zaman

Sandwell and West Birmingham Hospitals NHS Trust, Sandwell General Hospital, West Bromwich, West Midlands, B71 4HJ, United Kingdom.

Received : November 19, 2019

Published : December 13, 2019

ABSTRACT

Meckel's Diverticulum (MD) is the most common congenital malformation of the gastrointestinal tract and the only true diverticulum of the small bowel, resulting from the incomplete obliteration of the vitelline duct in the first 5 to 7 weeks of gestation. However, MD is rare, with a traditional prevalence of 2% in the general population. While the majority of MD never become symptomatic, potential for severe complications may arise secondary to diverticulitis with or without perforation, haemorrhage and obstruction. Considerable debate therefore exists whether or not to surgically resect MD found incidentally. Moreover, such complications present considerable diagnostic challenges, and given its rarity, are scarcely considered in the differentials of an acute abdomen.

We present one of the longest cases of giant MD reported in the literature, with non-perforated diverticulitis in a young adult male attending with an acute abdomen and normal inflammatory markers. He underwent successful, un-complicated laparoscopic resection. Histopathological analysis confirmed Meckel's diverticulitis in the absence of ectopic gastric or pancreatic tissue.

Keywords: Meckels Diverticulum; Congenital Malformations; Laparoscopy; Gastro-Intestinal Tract.

INTRODUCTION

Meckel's diverticulum (MD) is the most common congenital abnormality of the gastrointestinal tract [1,2]. First reported by Johann Meckel (1809), it arises from the incomplete involution of the omphalomesenteric duct in the 7th week of gestation [1,3,4], and is the only true diverticulum of the small intestine [5].

The maxim of twos is well established in traditional surgical teaching of MD: typically 2 inches long, 2 feet proximal to the ileocaecal valve, present in 2% of the population, twice as common in males and most often symptomatic in patients aged less than 2 years.

Recent evidence has shown a prevalence between 0.3-2.9% of the population [6-13]. Moreover, the largest systematic review of recent literature calculated a weighted mean distance of 52.3cm (7 to 200) from the ileocaecal junction on the antimesenteric border of the ileum, and a mean weighted length of 3.05cm (0.4 to 11), approximately 1 inch, with a mean diameter of 1.58cm (0.3 to 7) [2].

Giant MD, considered greater than 2 inches (or 5cm), considerably increases the risk of more severe forms of complications, particularly intestinal obstruction [14,15]. Increasing evidence also suggests a further correlation between size and severity of symptoms [2,16].

To our knowledge, herein we present one of the largest cases of MD reported in the literature, with implications for definitive surgical management.

CASE REPORT

A 23-year old Caucasian male presented to the acute surgical take with a short history (several hours) of generalised abdominal pain and one episode of vomiting.

Past medical history included laparoscopic appendicectomy in 2015 with histology revealing a neuroendocrine tumour. The patient was subsequently lost to follow-up. He was otherwise fit and well, on no regular medications and with no known allergies.

On examination his observations were within normal limits and he was maximally tender in the right iliac fossa. Blood results were borderline normal, with a mild leukocytosis (white cell count $12.0 \times 10^9/L$) and C-Reactive Protein (CRP) $<3\text{mg/L}$. Urea and electrolytes, liver function tests and serum amylase were within the normal range. Plain radiographs of the chest and abdomen were unremarkable.

Given his past history of malignancy and clinical findings, a Computed Tomography (CT) scan was performed (**Figure 1**), which showed a fluid-filled mass extending from the small bowel into the pelvis consistent with a Meckel's diverticulum.

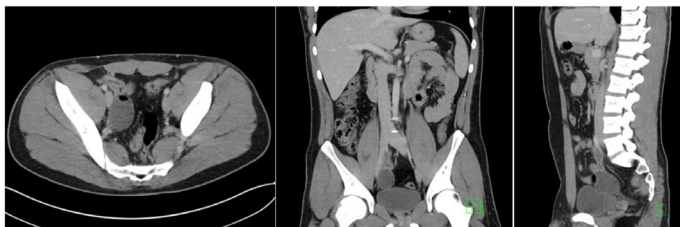


Figure 1: Intravenous-enhanced CT abdomen and pelvis performed in the portal venous phase.

Selected axial (i), coronal (ii) and sagittal (iii) images show a tubular, blind-ending fluid and gas-filled digestive structure arising from the distal ileum, with mild associated inflammatory change and small volume of peritoneal free fluid.

Diagnostic laparoscopy showed a MD 15.24cm in length (**Figure2**), which was excised using a laparoscopic surgical stapling device (Endo GIA™). The specimen was sent for histological analysis. The patient made a slow recovery jaded by a post-operative ileus which resolved conservatively and he was subsequently discharged home.

Histological findings indicated small intestinal type villous mucosa with no evidence of gastric or pancreatic mucosa, with severe inflammation and ulceration in keeping with Meckel's diverticulitis. No evidence of neoplasia was found.

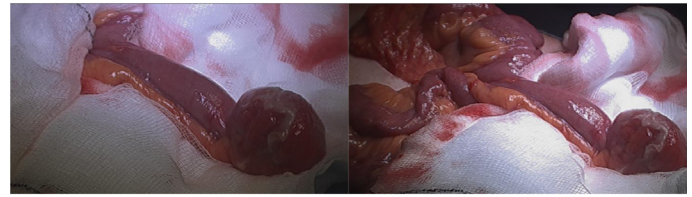


Figure 2: Laparoscopic views of giant MD with distal inflammation and oedematous changes.

DISCUSSION

MD is the only true diverticulum of the GI tract, comprising all three layers of the bowel wall and results from the incomplete atrophy of the vitelline duct. While 90% of MD are between 1 cm to 10 cm in length, 'giant MD' exceeding 5 cm are rare [17], with the largest recorded nearly a century ago measuring over 100 cm [18].

Although the majority of MD remain asymptomatic and are discovered incidentally, the lifetime incidence of symptomatic presentation remains between 4% to 9% [4,9,19], compared to 7% to 8% in appendicitis [16].

Intestinal obstruction is the most common complication of symptomatic MD, followed by haemorrhage from peptic ulceration with heterotopic mucosa, and diverticulitis with or without perforation, as in this case [20], accounting for 90% of symptomatic MD [19]. Obstruction arises from multiple aetiologies, including intussusceptions, whereby the MD is the lead point; mechanical volvulus around a persistent fibrous band attaching the MD to the umbilicus, or axial twisting around a narrow base; diverticular stricture; Littre's herniation, and inflammatory adhesions [2]. Rarer complications include umbilical abnormalities such as fistulation [21] and Meckelian cancers, generally diagnosed after 60 years of age [21,22].

Risk factors for developing complications are well established. Male sex, age under 50 years, length greater than 2 cm, and heterotopic presence of gastric or pancreatic mucosa increase the risk of complicated MD [23]. Presence of two, three (seen here) or four criteria increases the symptomatic prevalence to 25%, 42% and 70% respectively [23]. Nonetheless, a high index of suspicion is necessary for prompt diagnosis and treatment [24], with only 4% of MD identified pre-operatively either clinically or radiologically [25]. The presence of heterotopic mucosa (gastric and pancreatic tissue accounting for 97 %) is the most significant factor for determining the need for surgical intervention, and is closely correlated with haemorrhage. Symptomatic MD decreases with age (10, 13, 26-30), with over half of all children with MD requiring surgery under 5 years [31]. Interestingly, Negrea V et al. [32]

found a higher nerve fiber density in the walls of the Meckel's lined with intestinal mucosa, as seen in this case, compared to areas lined with ectopic gastric mucosa and the walls of the ileum. An inverse correlation exists between nerve fibre density and age, with higher nerve fibre density resulting in more intense local peristalsis, which may explain the observed predisposition to intussusception [32].

Giant MD has a higher incidence of obstruction [19,33]. Moreover, diverticulitis, torsion and volvulus are more common complications in longer MDs with a narrow base, while short MDs with a wider base stand at higher risk of intussusception [34]. Thus, an elongated variant with a narrow neck is more likely to result in torsion and diverticulitis, as seen in this case, whereas a short, wide-base diverticula may promote foreign body entrapment [15]. To the author's knowledge, this is one of the longest MD reported in the literature, with an abnormal presentation with near normal inflammatory markers.

Definitive management remains surgical excision of the MD with or without resection of adjacent small bowel, the latter preferred in the presence of severe inflammation [34]. Laparoscopic procedures have been shown to be safe and confer no worse outcomes or complications than open surgery, through single or 3 trocars, intra-peritoneally or exteriorization [35,36]. Debate exists whether silent MD should be resected when incidentally discovered. Recent reviews by Zani et al. [9] and Soltero et al. [19] found that resection of silent MD conferred a significantly higher post-operative complication rate than leaving *in situ*. Zani et al. found a 5.3% risk of postoperative complications after prophylactic resection and a 1.3% risk of developing symptoms after leaving it *in situ*. They also found no long-term complications associated with leaving the Meckel's in situ when reviewing articles that reported follow-up on patients with silent Meckel's left *in situ*, and estimated that more than 750 silent MD would have to be resected in order to preserve one life.

CONCLUSIONS

This case demonstrates the highly variable presentation of giant Meckel's diverticulitis, conferring considerable diagnostic and, given its considerable length, operative challenges. A diagnosis of MD should always be considered in the differential of an acute abdomen presenting with right iliac fossa pain, and multi-modality investigations including CT are recommended.

Acknowledgements

The authors are indebted to Dr Benjamin Butler, specialty

registrar in radiology, for his provision and reporting of the images in **Figure 1**.

REFERENCES

1. Uppal K, Tubbs RS, Matusz P, Shaffer K, Loukas M (2011) Meckel's diverticulum: a review. *Clin Anat* 24(4): 416-422.
2. Hansen CC, Soreide K (2018) Systematic review of epidemiology, presentation, and management of Meckel's diverticulum in the 21st century. *Medicine (Baltimore)* 97(35): e12154.
3. Sagar J, Kumar V, Shah DK (2006) Meckel's diverticulum: a systematic review. *J R Soc Med* 99(10): 501-505.
4. Elsayes KM, Menias CO, Harvin HJ, Francis IR (2007) Imaging manifestations of Meckel's diverticulum. *AJR Am J Roentgenol* 189(1): 81-88.
5. Tenreiro N, Moreira H, Silva S, Madureira L, Gaspar J, Oliveira A (2015) Unusual presentation of a Meckel's diverticulum: A case report. *Int J Surg Case Rep* 16: 48-51.
6. Palanivelu C, Rangarajan M, Senthilkumar R, Madankumar MV, Kavalakat AJ (2008) Laparoscopic management of symptomatic Meckel's diverticula: a simple tangential stapler excision. *JLS Society of* 12(1): 66-70
7. Freeman HJ (2001) Meckel's diverticulum in Crohn's disease. *Can J Gastroenterol* 15(5): 308-311.
8. Tauro LF, George C, Rao BS, Martis JJ, Menezes LT, Shenoy HD (2010) Asymptomatic Meckel's diverticulum in adults: is diverticulectomy indicated? *Saudi J Gastroenterol* 16(3):198-202
9. Zani A, Eaton S, Rees CM, Pierro A (2008) Incidentally detected Meckel diverticulum: to resect or not to resect? *Ann Surg* 247(2): 276-281.
10. Aarnio P, Salonen IS (2000) Abdominal disorders arising from 71 Meckel's diverticulum. *Ann Chir Gynaecol* 89(4): 281-284.
11. Sancar S, Demirci H, Sayan A, Arikan A, Candar A (2015) Meckel's diverticulum: ten years' experience. *Ulus Cerrahi Derg* 31(2): 65-67.
12. Shalaby RY, Soliman SM, Fawy M, Samaha A (2005) Laparoscopic management of Meckel's diverticulum in children. *J Pediatr Surg* 40(3): 562-567.
13. Ueberrueck T, Meyer L, Koch A, Hinkel M, Kube R, Gastinger I (2005) The significance of Meckel's diverticulum in appendicitis—a retrospective analysis of 233 cases. *World J Surg* 29(4): 455-458.

14. Akbulut S, Yagmur Y (2014) Giant Meckel's diverticulum: An exceptional cause of intestinal obstruction. *World J Gastrointest Surg* 6(3): 47-50.
15. Tan YM, Zheng ZX (2005) Recurrent torsion of a giant Meckel's diverticulum. *Dig Dis Sci* 50(7): 1285-1287.
16. Bhangu A, Søreide K, Di Saverio S, Assarsson JH, Drake FT (2015) Acute appendicitis: modern understanding of pathogenesis, diagnosis, and management. *Lancet* 386(10000): 1278-1287.
17. Torii Y, Hisatsune I, Imamura K, Morita K, Kumagaya N, Nakata H (1989) Giant Meckel diverticulum containing enteroliths diagnosed by computed tomography and sonography. *Gastrointest Radiol* 14(1): 167-169.
18. Tisdall FF (1928) An unusual Meckel's diverticulum as a cause of intestinal hemorrhage. *Am J Dis Child* 36(6): 1218-1223.
19. Soltero MJ, Bill AH (1976) The natural history of Meckel's diverticulum and its relation to incidental removal: a study of 202 cases of diseased Meckel's diverticulum found in King County, Washington, over a fifteen year period. *Am J Surg* 132(2): 168-173.
20. Levy AD, Hobbs CM (2004) From the archives of the AFIP: Meckel diverticulum: radiologic features with pathologic correlation. *Radiographics* 24(2): 565-587.
21. Durakbasa CU, Okur H, Mutus HM, Bas A, Ozen MA, Sehrialti V, et al. (2010) Symptomatic omphalomesenteric duct remnants in children. *Pediatr Int* 52(3): 480-484.
22. Thirunavukarasu P, Sathaiah M, Sukumar S, Bartels CJ, Zeh III H, Lee KK, et al. (2011) Meckel's diverticulum - a high-risk region for malignancy in the ileum: insights from a population-based epidemiological study and implications in surgical management. *Ann Surg* 253(2): 223-230
23. Mackey WC, Dineen P (1983) A fifty year experience with Meckel's diverticulum. *Surg Gynecol Obstet* 156(1): 56-64.
24. Rivas H, Cacchione RN, Allen JW (2003) Laparoscopic management of Meckel's diverticulum in adults. *Surg Endosc* 17(4): 620-622.
25. Lüdtke FE, Mende V, Köhler H, Lepsien G (1989) Incidence and frequency of complications and management of Meckel's diverticulum. *Surg Gynecol Obstet* 169(6): 537-542.
26. Park JJ, Wolff BG, Tollefson MK, Walsh EE, Larson DR (2005) Meckel diverticulum: the Mayo Clinic experience with 1476 patients (1950-2002). *Ann Surg* 241(3): 529-533.
27. Feller AA, Movson J, Shah SA (2003) Meckel diverticulum: a geriatric disease masquerading as common gastrointestinal tract disorders. *Arch Intern Med* 163(17): 2093-2096.
28. Ero AP, Martinez-Barba E, Canteras M, Rodriguez JM, Castellanos G, Parrilla P (2002) Surgical management and complications of Meckel's diverticulum in 90 patients. *Eur J Surg* 168(1): 8-12.
29. Varcoe RL, Wong SW, Taylor CF, Newstead GL (2004) Diverticulectomy is inadequate treatment for short Meckel's diverticulum with heterotopic mucosa. *ANZ J Surg* 74(10): 869-872.
30. Lohsiriwat V, Sirivech T, Laohapensang M, Pongpaibul A (2014) Comparative study on the characteristics of Meckel's diverticulum removal from asymptomatic and symptomatic patients: 18-year experience from Thailand's largest university hospital. *J Med Assoc Thai* 97(5): 506-512.
31. Alemayehu H, Hall M, Desai AA, Peter SD, Snyder CL (2014) Demographic disparities of children presenting with symptomatic Meckel's diverticulum in children's hospitals. *Pediatr Surg Int* 30(6): 649-653.
32. Negrea V, Gheban D (2012) Nervous structure of Meckel's diverticulum in children. *Rom J Morphol Embryol* 53(3): 573-576.
33. Cartanese C, Petitti T, Marinelli E, Pignatelli A, Martignetti D, Zuccarino M, et al. (2011) Intestinal obstruction caused by torsed gangrenous Meckel's diverticulum encircling terminal ileum. *World J Gastrointest Surg* 3(7): 106-109.
34. Caiazzo P, Albano M, Del Vecchio G, Calbi F, Loffredo A, Pastore M, et al. (2011) Intestinal obstruction by giant Meckel's diverticulum. Case report. *Il G Chir* 32(11-12): 491-494.
35. Ding Y, Zhou Y, Ji Z, Zhang J, Wang Q (2012) Laparoscopic management of perforated Meckel's diverticulum in adults. *Int J Med Sci* 9(3): 243-247
36. Clark JM, Koontz CS, Smith LA, Kelley JE (2008) Video-assisted transumbilical Meckel's diverticulectomy in children. *Am Surg* 74(4): 327- 329.